

# Vasoview 6 Pro

Endoscopic Vessel Harvesting System  
Training Manual

# Introduction

This training manual for endoscopic vessel harvesting (EVH) using the Vasoview 6 Pro Endoscopic Vessel Harvesting System is designed to provide the operator with step-by-step instructions for performing the EVH procedure.

Included in this document are preoperative considerations, intra-operative technique tips, postoperative recommendations and troubleshooting suggestions. This document is not intended to replace reading the product Instructions for Use, nor is it intended to replace the independent judgment of the medical professional performing the procedure.

## **Vasoview 6 Pro**

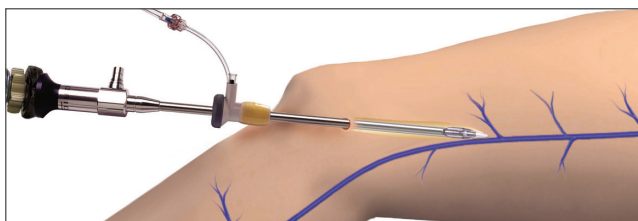
The Vasoview 6 Pro Endoscopic Vessel Harvesting System is the product of multiple generations of learning and experience in EVH. Getinge combines leading-edge advances in product design with a solid history of surgical success to provide the most advanced and effective EVH solutions available. Vasoview products are supported by clinical consultants who have both hospital surgical experience and industry-leading training in EVH. The Vasoview System provides real options to cardiac surgeons and their surgical team and real benefits to the patients they serve.

# Table of Contents

<b>1 Endoscopic Vessel Harvesting Saphenous Vein Procedure-at-a-Glance</b> .....	4
<b>2 Endoscopic Vessel Harvesting Radial Artery Procedure-at-a-Glance</b> .....	5
<b>3 Operating Room Instrumentation and Equipment</b> .....	6
<b>4 Equipment Testing</b> .....	7
<b>5 Endoscopic Vessel Harvesting Procedure: Saphenous Vein</b> .....	8
Patient Positioning and Preparation.....	8
Incision Site.....	10
Inserting the 7 mm Endoscope with Attachable Dissection Tip.....	11
CO <sub>2</sub> Insufflation.....	12
Endoscopic Dissection.....	13
Branch Cauterization and Transection.....	16
Optimizing Visualization.....	19
Guidelines for Safe and Effective Use of BiSector™ Bipolar Ligating Forceps.....	20
Running the Vein.....	21
Distal Transection and Ligation.....	22
Vein Removal and Preparation.....	23
Closing and Dressings.....	23
<b>6 Endoscopic Vessel Harvesting Procedure: Radial Artery</b> .....	24
Patient Positioning and Preparation.....	24
Incision and Tourniquet Deployment.....	25
Endoscopic Dissection.....	25
Fasciotomy.....	27
Branch Cauterization and Transection.....	27
Transection and Retrieval of the Radial Artery.....	28
Hemostasis and Conduit Preparation.....	29
<b>7 Documentation</b> .....	30
<b>8 Nursing Considerations</b> .....	31
<b>9 Case Setup</b> .....	32
<b>10 Postoperative Procedures</b> .....	33
<b>11 Troubleshooting</b> .....	34
<b>12 Appendix A: Eight Steps for Tying a Ligation Loop</b> .....	35

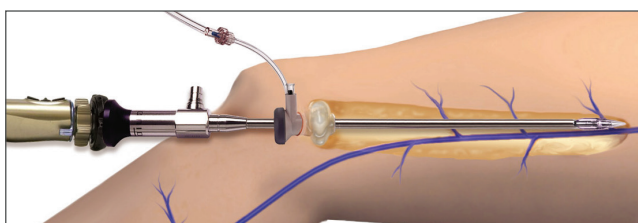
# Endoscopic Vessel Harvesting

## Saphenous Vein Procedure-at-a-Glance



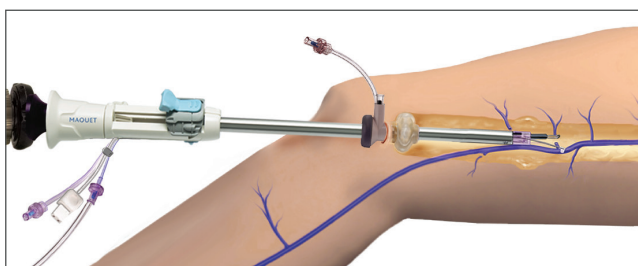
### Incision

Create an incision in the area near the knee, over the greater saphenous vein. Attach the Dissection Tip to the end of the 7 mm endoscope. Insert the 7 mm endoscope into the incision and visualize on the video monitor.



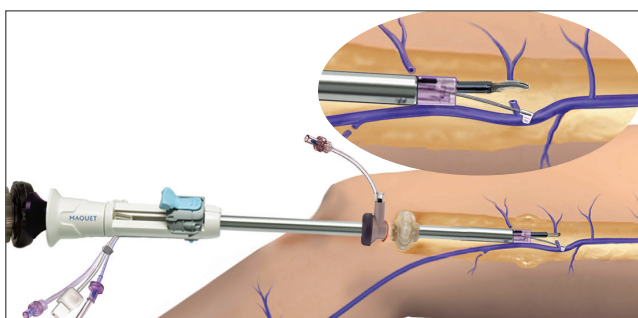
### Initiating CO<sub>2</sub> Insufflation

Advance the Short Port Blunt Tip Trocar (BTT) into position, and insufflate CO<sub>2</sub> gas to create a tunnel. Perform anterior, posterior and branch dissection with the Dissection Tip.



### Cauterizing and Transecting Branches

After removing the Dissection Tip from the endoscope insert the endoscope into the Vasoview 6 Pro Harvesting Cannula. Insert the Vasoview 6 Pro Harvesting Cannula to cauterize and transect branches, using the BiSector™ Bipolar Ligating Forceps.

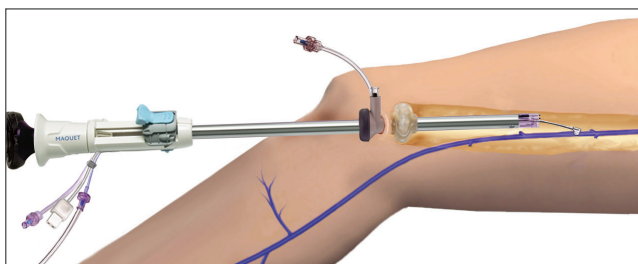


### Enhanced Visualization

For enhanced visualization during vessel branch cauterization and transection, transfer the CO<sub>2</sub> source from the BTT CO<sub>2</sub> Insufflation Port to the Distal Insufflation CO<sub>2</sub> Port on the Vasoview 6 Pro Harvesting Cannula.

### Running the Vessel

Deploy the C-Ring from the Vasoview 6 Pro Harvesting Cannula, engage the vein with the C-Ring and run the length of the vein to ensure that it is completely free and no branches remain.



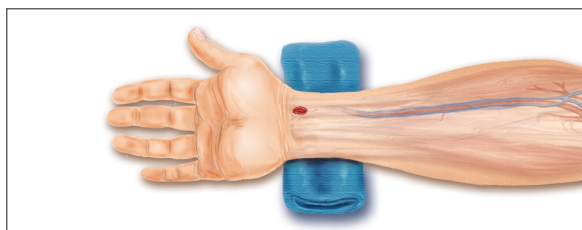
### Transection and Retrieval

Make a stab wound over the distal end of the tunnel, clamp the saphenous vein, pull it through the stab wound. Transect the vein. Ligate the terminal end of the vein. Retrieve the harvested vein from the original incision at the knee.



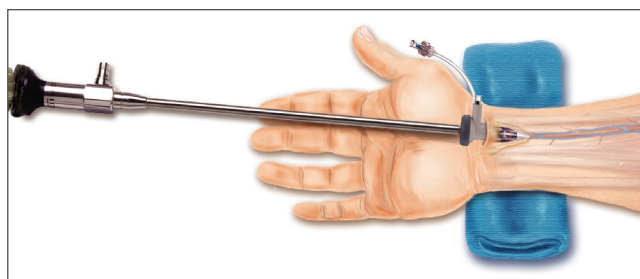
# Endoscopic Vessel Harvesting

## Radial Artery Procedure-at-a-Glance



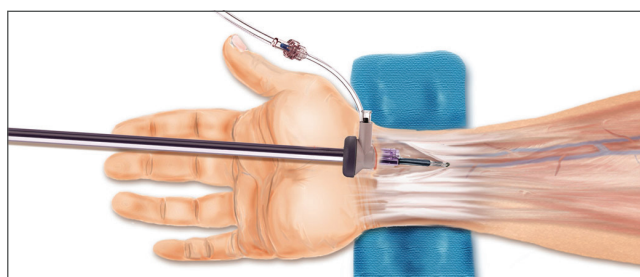
### Incision

Beginning just proximal to the wrist crease, create a longitudinal incision. Attach the Dissection Tip to the end of the 7 mm endoscope. Insert the 7 mm endoscope into the incision and visualize on the video monitor.



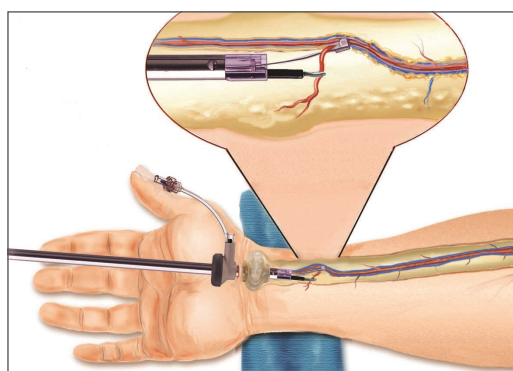
### Initiating CO<sub>2</sub> Insufflation

Insert the Short Port Blunt Tip Trocar (BTT) into position and begin CO<sub>2</sub> insufflation. Perform anterior, posterior, and lateral dissection of the radial artery pedicle with the Dissection Tip on the 7 mm endoscope.



### Fasciotomy

After removing the Dissection Tip from the endoscope insert the endoscope into the Vasoview 6 Pro Harvesting Cannula. Insert the Vasoview 6 Pro Harvesting Cannula. Using the BiSector™ Bipolar Ligating Forceps, release the fascia, cutting it from the distal to the proximal forearm.

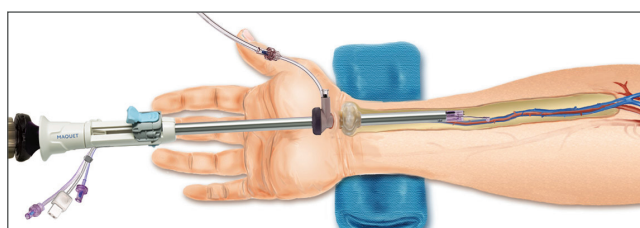


### Cauterizing and Transecting Branches

Use the C-Ring to protect the radial artery pedicle and expose the branches. Using the BiSector tool, cauterize and transect branches.

### Running the Vessel

Deploy the C-Ring from the Vasoview 6 Pro Harvesting Cannula, engage the radial artery with the C-Ring and run the length of the artery to ensure that it is completely free and that no intact branches remain.




### Transection and Retrieval

Make a stab incision near the elbow, clamp the radial artery pedicle and pull it through the stab incision. Transect the radial artery. Ligate the proximal radial artery stump, and then in retrograde fashion, retrieve the radial artery pedicle from the original incision at the wrist.

# Operating Room

## Instrumentation and Equipment

### Vasoview 6 Pro Endoscopic Vessel Harvesting System



#### Additional Items:

- Bipolar Cord (sterile)
- Anti-fog solution
- Surgical instruments used for open harvest
- Bovie

#### Video Equipment:

- Camera box
- Video monitor
- Light source
- Insufflator
- Insufflator tubing (sterile)
- CO<sub>2</sub> source
- Fiber optic cable with appropriate scope adaptor end
- Camera compatible to Endoscope

# Equipment Testing

- Prior to starting the EVH procedure, turn on all of the equipment on the video tower (video monitor, camera, light source, and insufflator). Be sure that the electric cords are attached to the back of each piece of equipment. Once all equipment checks are performed, turn the system completely off until the procedure begins.
- The monitor should show color bars until a camera head is plugged into the camera box. If the color bars are not balanced, press the reset button to bring them back to the factory setting.
- The camera head should be plugged into the camera box to check for a clear picture prior to sterilization (except in the case of terminal sterilization).
- The light source should be checked to be sure that light is coming from the unit. Do not look directly into the light.
- If the fiber optic light cable will be sterilized with the camera head, it should be checked for damaged fiber optics. To do this, hold one end toward a direct light source and look into the other end. If it illuminates with no more than one-third of the area grayed, the cable is in good order. If a significant portion of the cable does not illuminate (reflects a blackened area), use a different cable. If the fiber optic cables need to be terminally sterilized, this quality-control procedure should take place prior to sterilization.
- The endoscope should be checked in two ways prior to sterilization. First, look through the endoscope eyepiece and be sure that the image is clear. Second, hold the light post up to a direct light source and look directly into the distal end of the endoscope. A complete circle of light should be visible around the distal tip.
- Turn the CO<sub>2</sub> gas tank to the open position and check to be sure there is either a full tank of gas or an extra tank available in the room. Be sure that the gas is flowing from the unit when the insufflator is turned on. Set the insufflator at 3 to 5 L/min flow and 10 to 12 mmHg pressure.
- Be sure that the bipolar foot pedal is connected to the correct port of the electrocautery generator.

# EVH Procedure

## Saphenous Vein

### Patient Positioning and Preparation

#### Patient Positioning

Place the patient in a supine position. Externally rotate the leg with the knee flexed and with support behind the knee and the thigh. (Figure 1)

#### Surgical Preparation and Vein Location

Prior to the skin prep, assess the patient to select the incision site around the knee area. Once the intended incision site is identified, mark the area with a surgical marker.

The saphenous vein can usually be found by using anatomical landmarks. An ultrasonic doppler may be used to help locate the vein. If needed, use the doppler prior to the patient prep and then mark the site with a surgical marker. If appropriate, vein mapping may be performed preoperatively. Note that the saphenous vein lies fairly posterior in relationship to the patella. Perform skin prep according to hospital protocol.

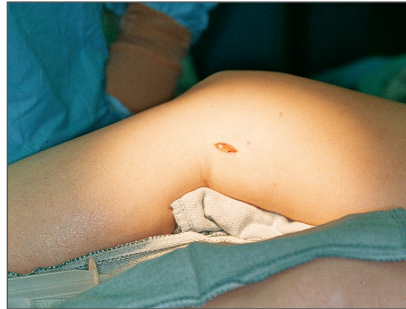

Figure 1

### Product Assembly

- Attach the 7 mm Extended Length Endoscope to the camera coupler. Attach the light cable to the post on the endoscope. Focus the endoscope on a gauze pad and white balance the video camera as described below. Ensure proper orientation of the camera head. It is important to maintain correct orientation throughout the procedure.
- Thread the Dissection Tip to the distal end of the endoscope until the proximal edge of the Dissection Tip lines up with the indicator etched on the endoscope shaft. (Figures 2 and 3)
- Insert the endoscope with attached Dissection Tip through the BTT. Ensure that the Endoscope Seal is on the BTT (the BTT comes packaged with this seal attached). (Figure 4)

### Proper White Balancing

White balancing is the process by which the camera learns what “white” is. This process sets the full range of color through the camera.

- To white balance the camera, attach the camera head and fiber optic cables to the endoscope and hold a piece of white gauze approximately 1.5 inches from the distal end of the endoscope. (Figure 5)
- Focus the camera and ensure that only white is visible. Press the white-balance button from either the camera head or camera box, depending on the camera system. Hold the camera and endoscope still until the system indicates white balance is completed.

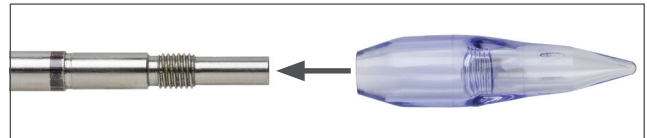


Figure 2



Figure 3



Figure 4




Figure 5

## Incision Site

### Selecting the Incision Site

There are several factors to consider when selecting the incision site, such as operator preference, number of grafts needed, and whether the upper or lower leg is used for the vein harvest.

There are two commonly used incision sites: (Figure 6)

- Below the knee: Palpate along the tibia until reaching the medial tibial epicondyle. Make a 2 cm incision along the posterior border of the tibial epicondyle. (Figure 7)
- Above the knee: Make a 2 cm incision in the thigh where the vein lies in the groove between the sartorius and gracilis muscles. (Figure 8)

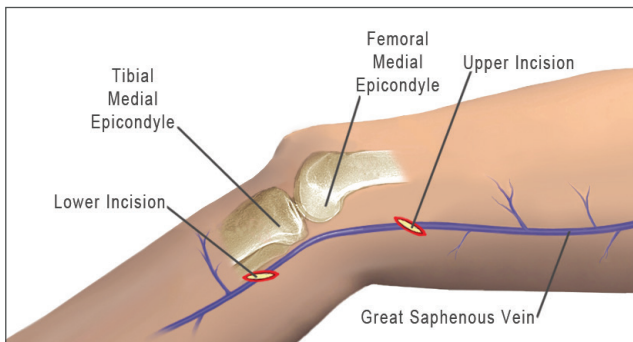


Figure 6

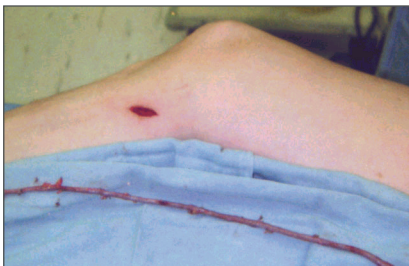

Figure 7

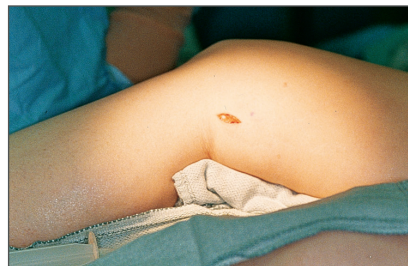

Figure 8

### Making the Incision

- Once the incision site has been identified, make a 2 cm skin incision directly over the vein.
- A transverse, longitudinal or oblique incision may be used depending on operator preference.
- Under direct visualization, dissect the subcutaneous tissue to expose the Greater Saphenous Vein.
- Continue dissection of the anterior surface of the vein in the direction of planned harvesting, creating a small space approximately the length of the distal end of the BTT to ensure easy insertion.



## Inserting the 7 mm Endoscope with Attachable Dissection Tip

- Under direct visualization, insert the dissection tip into the space created, and place it onto the anterior surface of the saphenous vein. (v) Note (on the video monitor) the color of the vein and the surrounding yellow fatty tissue. It is important to always identify the vein prior to advancement of the instrument. (Figure 9) If the vein is very superficial (adhered to the skin) or there is great resistance when advancing the Dissection Tip on the anterior surface of the vein, place the Dissection Tip on the posterior surface of the vein.
- Advance the endoscope approximately 4 cm, then slide the BTT through the incision site and into the previously dissected space. (Figure 10)

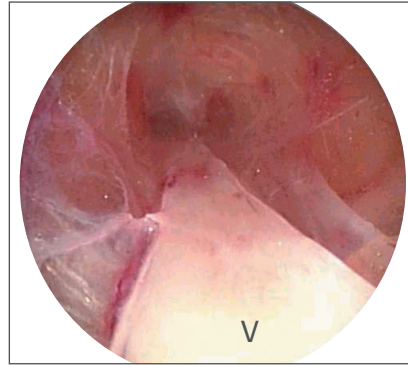


Figure 9

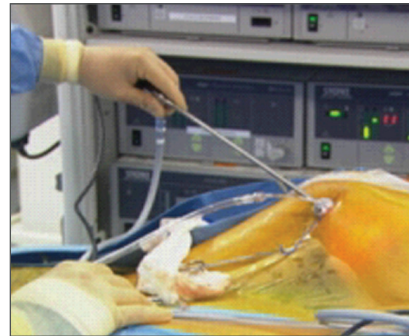


Figure 10

## CO<sub>2</sub> Insufflation

- Connect the CO<sub>2</sub> insufflation tubing to the clear flexible CO<sub>2</sub> Insufflation Port on the BTT and begin insufflation of CO<sub>2</sub>. Ensure the CO<sub>2</sub> Insufflator is set to the proper flow and pressure settings.  
CO<sub>2</sub> Flow: 3 – 5 L/min  
CO<sub>2</sub> Pressure: 10 – 12 mmHg  
The goal is to delineate a tissue plane for easier dissection and to maintain the tunnel.
- If desired pressure is not obtained in the tunnel, the slip tip syringe provided can be used to inflate the balloon on the BTT. Inflate the balloon with the minimal amount of air needed to create an adequate seal (0 – 25 cc's of air). If there is obvious leakage around the incision, use a purse-string suture to ensure a tight seal around the BTT.
- Once the CO<sub>2</sub> insufflation has begun, note the initial "webbing" effect or partial separation of tissues from the saphenous vein. (Figure 11)

### Technique Tips

- If partial separation of tissue from saphenous vein is not observed, check that the CO<sub>2</sub> is flowing, the pressure setting is 10 – 12 mmHg, and the tubing is connected properly to the BTT and the insufflator. Also check the CO<sub>2</sub> tank to ensure it is in the open position, with an adequate amount of CO<sub>2</sub>. (See Troubleshooting Section)

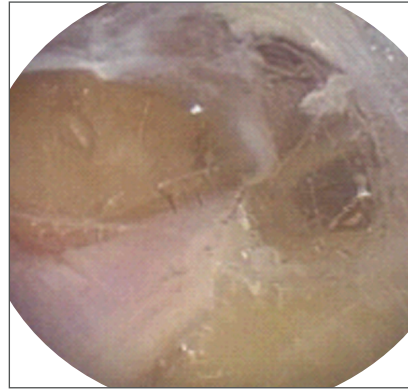

Figure 11



## Endoscopic Dissection

The endoscope with attachable Dissection Tip is used to dissect surrounding subcutaneous and connective tissue from the saphenous vein and to dissect the branches. The atraumatic Dissection Tip performs the blunt dissection. CO<sub>2</sub> insufflation aids the dissection by enabling constant visualization, reduces bleeding, and helps maintain a working space. (Figure 12) Mastery of the dissection will enable clear exposure and easy access for branch cauterization and transection.

The goal of dissection is to expose the vein so that it is suspended by its branches in the center of the working space. (Figures 13 and 14)

To ensure the best results, follow these basic three steps which are described on the following pages:

- Step 1: Anterior Dissection
- Step 2: Posterior Dissection
- Step 3: Branch Dissection

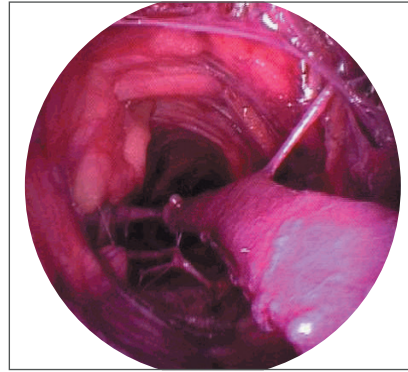


Figure 12

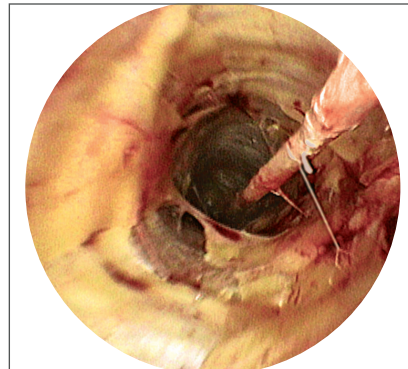


Figure 13

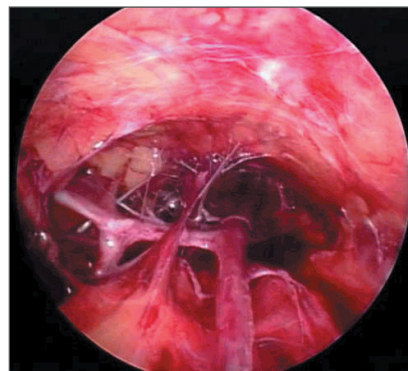


Figure 14

### Step 1: Anterior Dissection

Position the Dissection Tip on the anterior surface of the vein. (Figure 15) Begin dissecting until you have reached the desired length of vein.

#### Technique Tips

- The Dissection Tip should be positioned between the vein surface and the surrounding fatty tissue.
- To ensure the maximum effect of the CO<sub>2</sub> insufflation and to create the optimal tunnel, it is important to keep the Dissection Tip close to the vein and not stray into the surrounding tissue. This helps to avoid creating multiple small spaces or pseudo-tunnels.
- Use smooth, controlled, short strokes when advancing the endoscope, allowing CO<sub>2</sub> to reach the tip and facilitate dissection.
- Use your dominant hand to guide the endoscope and your free hand on the external operative area to facilitate dissection with external manipulation. If tissue collects on the Dissection Tip, use the free hand on the outside of the leg to palpate the tip and dislodge the tissue. (Figure 16)
- Maintain the endoscope in a position parallel to the vein. This will help to avoid diving into the vein, thereby minimizing the risk of perforation. Correct camera orientation is necessary and should be maintained throughout the procedure.
- If at any point, the vein is no longer visible, retract the endoscope until the vein is again visualized, ensure proper camera orientation and proceed with the dissection.

### Preventing Avulsions or Perforations

- A perforation may occur if the vein appears to surround the Dissection Tip. The video monitor may reveal a fine swirling or "halo" effect. If this occurs, stop advancing and withdraw the endoscope until the swirling effect disappears. Then continue dissection ensuring the endoscope is in the proper tissue plane.
- Watch for anterior branches and direct the Dissection Tip around them to prevent an avulsion.
- Some branches may require additional dissection in order to allow easy passage around the branch while providing minimal branch tension.

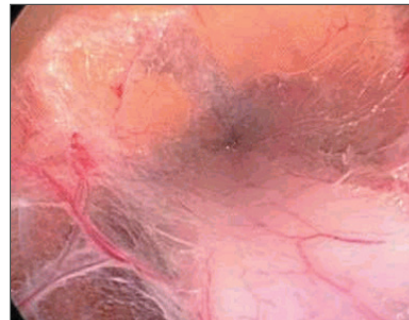


Figure 15

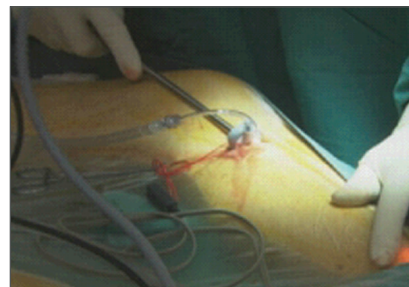


Figure 16

### Step 2: Posterior Dissection

Withdraw the endoscope to the tip of the BTT. Repeat dissection along the posterior aspect of the vein, using a gentle forward motion, until reaching the distal end of the tunnel. (Figure 17) Note the further benefit of CO<sub>2</sub> insufflation in separating tissue planes.

#### Technique Tips

- Maintain the Dissection Tip close to the posterior vein surface when dissecting the surrounding tissue.
- Advance the endoscope 180 degrees from the plane of the anterior dissection which will help provide maximum dissection.
- Watch for posterior branches and direct the Dissection Tip around them to prevent an avulsion.

### Step 3: Branch Dissection

Withdraw the endoscope to the BTT. Begin dissecting along the vein, removing any remaining tissue that is still adhered. (Figure 18) When a branch is encountered, dissect it with short, controlled gentle probes with the Dissection Tip. Continue until all branches are adequately exposed to facilitate cauterization and transection. (Figure 19)

#### Technique Tips

- Be sure to expose each branch adequately, enabling easy access when using the Vasoview 6 Pro Harvesting Cannula.
- Larger branches may require additional dissection to achieve additional branch length. This will give increased distance between the vein and the branch for later cauterization.
- Until experience is gained, be careful not to advance the endoscope too quickly when dissecting around branches. External manipulation by your free hand will aid dissection by bringing the tissue or branches to the Dissection Tip. As experience level increases, this will become even more beneficial.

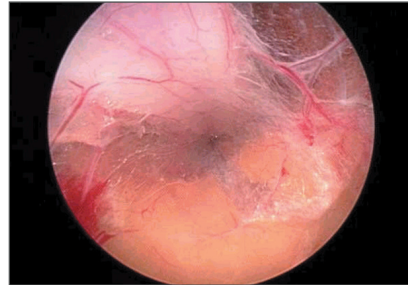


Figure 17

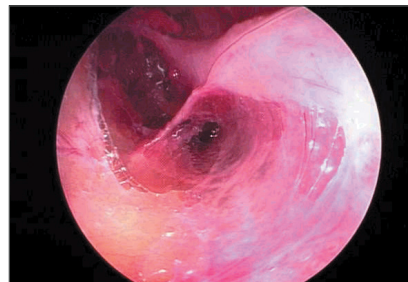


Figure 18

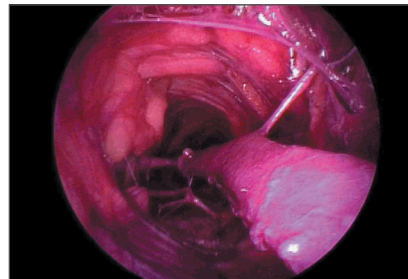


Figure 19

## Branch Cauterization and Transection

The Vasoview 6 Pro Harvesting Cannula is used for branch cauterization and transection. The integrated instrument aims the endoscope, BiSector™ Bipolar Ligating Forceps, and C-Ring in one direction, allowing easy vein protection and branch transection. By design, the BiSector tool position will always be opposite the C-Ring “struts.” (Figure 20)

- After dissection of the vein, withdraw the endoscope from the tunnel leaving the BTT in place. Remove the Dissection Tip by unthreading it off the endoscope. Remove the Endoscope Seal from the BTT and replace it with the Harvesting Cannula Seal.
- Apply anti-fog solution to the distal tip of the endoscope if desired.
- Insert the endoscope into the bell handle of the Vasoview 6 Pro Harvesting Cannula. The endoscope is secured with an audible “click,” locking it into place. (Figure 21)
- Attach the Bipolar Cord to the Vasoview Harvesting Cannula. Ensure that the Bipolar Cord is connected to the bipolar generator. Place the bipolar foot pedal by the harvester.
- Set the bipolar generator wattage according to recommendations in the Vasoview 6 Pro Instructions For Use (settings differ by type of generator).
- Pre-test the BiSector tool to verify complete electrical activity and generator setting. (Complete instructions are noted in the Vasoview 6 Pro Instructions For Use.)
- Ensure that the BiSector tool and C-Ring are fully retracted into the Harvesting Cannula, then insert the Harvesting Cannula through the BTT. Advance the Harvesting Cannula to the most distal portion of the tunnel, maintaining a central position to avoid endoscope sliming. Always maintain correct orientation of the camera.



Figure 20




Figure 21

- Use the C-Ring Slider to advance the C-Ring and place it on the vein. (Figure 22a) Moving distal to proximal, retract the Harvesting Cannula down the tunnel.
- Once a branch is encountered, keeping the C-Ring distal to the branch, advance the BiSector™ tool by moving the BiSector Rotating Carriage on the handle forward. (Figure 22b) Ensure that the BiSector tool blade is extended prior to capturing the branch – depress the proximal end of the BiSector Cutting Toggle to extend the blade.
- Rotate the BiSector tool using the carriage to orient the blade upward for ease of visualization and branch capture. (Figures 23a - 23b)

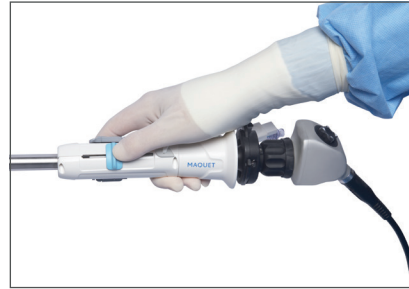


Figure 22a

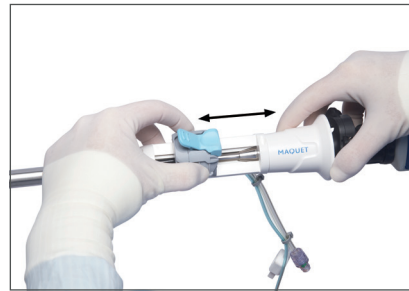


Figure 22b

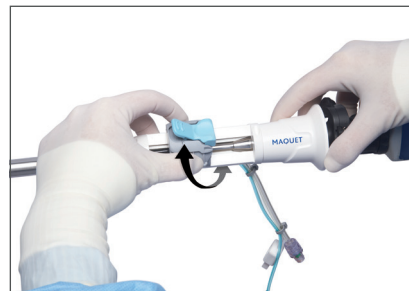

Figure 23a

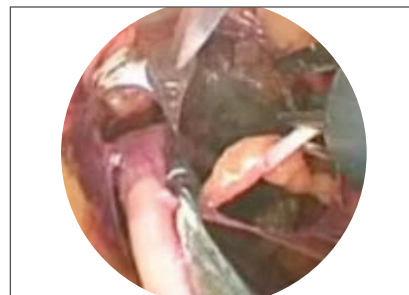


Figure 23b

- When the branch is captured, use the BiSector Carriage to rotate the BiSector™ tool away from the vein, adding slight tension to the branch. (Figure 24) Maintain a 3 – 5 mm distance from the main trunk of the saphenous vein, while activating the bipolar cautery for 1 – 2 second increments or until blanching of the vessel branch occurs. Transect the blanched area of the vessel branch using the BiSector tool.
- Continue to inspect the surgical site for hemostasis. Cauterize with the BiSector tool as necessary to achieve hemostasis, ensuring that the blade is not extended during spot cautery.

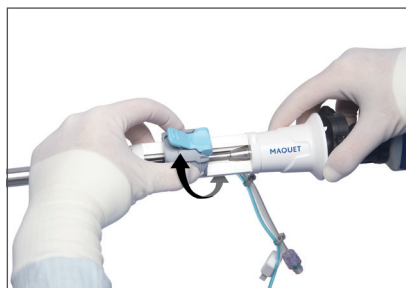

Figure 24

#### BiSector Tool Tips

- While in the tunnel, ensure the blade is extended prior to capturing the branches. This will help optimize procedural steps. To extend, press the Cutting Toggle forward.
- Prior to cauterization, advance the BiSector tool until the vein branch is between the electrodes of the BiSector tool.
- If there is not enough distance to allow for rotation of the BiSector tool away from the main vessel, perform more dissection (or fasciotomy) to further expose the branch.
- Set the bipolar generator wattage according to the type of bipolar generator being used. Refer to the Vasoview 6 Pro Instructions for Use for specific generator cautery settings.
- Should the BiSector tool blade need cleaning, use the tunnel walls to clean off fat, or pull the entire system out of the leg to clean it.
- For spot cautery, make sure the blade is not extended. Use the edges of the BiSector tool to touch the site where spot cautery is needed.
- Fasciotomy can be performed bite by bite. Cut, then immediately move the BiSector tool forward to capture more fascia.
- Blunt dissection can be performed using the distal tips of the BiSector tool to make windows.
- Sharp dissection can be performed using a cutting action.

## Optimizing Visualization

- The Vasoview 6 Pro also provides distal insufflation at the site of branch ligation. Remove the CO<sub>2</sub> source from the BTT CO<sub>2</sub> Insufflation Port; a one-way valve is designed to maintain the insufflated tunnel during this step. Attach the CO<sub>2</sub> source to the Distal Insufflation Port on the Harvesting Cannula. This will deliver CO<sub>2</sub> insufflation to the distal end of the Harvesting Cannula.
- If the distal lens of the endoscope becomes obscured by blood or fat, use the integrated endoscope wash feature. Fill the 5 cc syringe with saline and attach it to the blue Scope Wash Port extending from the Harvesting Cannula handle. Depress the syringe plunger slightly to wet the scope lens and clear obstructive debris or fluid. (Figure 25)
- Alternatively, the endoscope can be removed to clean the lens directly with a sterile gauze pad. Remove the endoscope from the bell handle leaving the Harvesting Cannula in the tunnel to maintain surgical position. When the endoscope is cleaned, reinsert it back into the bell handle of the Vasoview 6 Pro Harvesting Cannula.

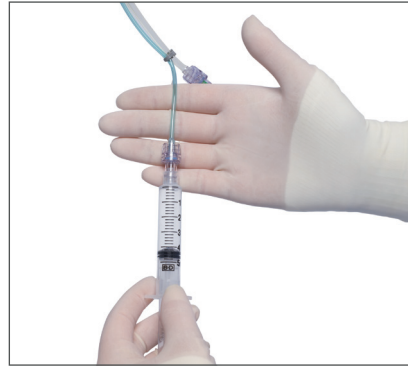

Figure 25



## Guidelines for Safe and Effective Use of the BiSector™ Bipolar Ligating Forceps

- Ensure the generator wattage is set according to recommendations in the Vasoview 6 Pro Instructions for Use (settings differ by type of generator).
- Always keep the BiSector tool and BiSector tool blade in view during coagulation.
- Utilize the C-Ring to provide adequate distance between the saphenous vein and the vessel branches to facilitate branch cauterization and transection.
- Coagulate for 1 – 2 second increments only. Monitor tissue dehydration and blanching. Further coagulation may be required for large vessel branches.
- Keep the BiSector tool and C-Ring retracted into the Harvesting Cannula during cannula insertion, advancement, and removal.
- Remove any fat or coagulum from the BiSector tool to insure proper coagulation.

## Technique Tips

- Use the internal diameter of the C-Ring (5 mm) as a guide for measuring distance. Advance the Harvesting Cannula to the distal end of the tunnel to begin vessel branch cauterization and transection, working back towards the incision. If branches prohibit advancement of the Harvesting Cannula, it may be less traumatic to the vein to perform vessel branch harvesting starting at the proximal end of the tunnel.
- Always ensure the C-Ring is behind the vessel branch that is being cauterized and transected.
- After cauterizing and transecting a branch, observe for bleeding. If bleeding is noted, spot cauterization can be performed by advancing the BiSector tool to the bleeding point and cauterizing the bleeding area. (Figure 26)
- When cauterizing and transecting branches, be sure to have the C-Ring as close to the branch as possible before rotating. This will allow the ability to cauterize and cut the branch further away from the vein.
- When retracting the instrument with the vein in the C-Ring, if the vein appears to be turning (or snaking) around the instrument, rotate the Harvesting Cannula in the direction of the turning (or snaking). Often this represents that a branch is going to be encountered.
- Always retract the BiSector tool into the Harvesting Cannula when not in use. (Figure 27)
- Try to keep the C-Ring with the vein in place in the center of the tunnel at all times. (Figure 28)

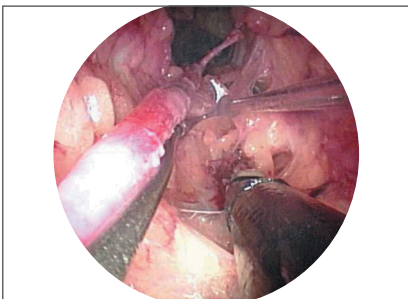


Figure 26

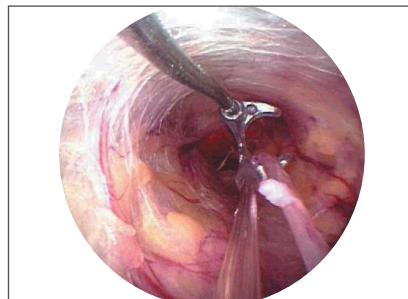


Figure 27

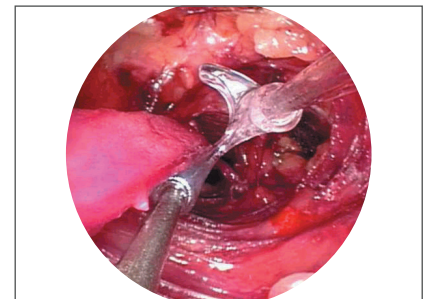


Figure 28



## Running the Vein

The purpose of running the vein is to identify any intact branches or adherent tissue prior to distal vessel transection.

- Once all branches have been cauterized and transected, run the C-Ring along the entire length of the vein to ensure that all branches have been transected. (Figures 29a and 29b)
- Make a second pass with the C-Ring in the opposite orientation to ensure that all branches and connective tissue are free from the vessel. (Figure 30)
- Identify and divide any connective tissue or branches that are still adhered to the vein.

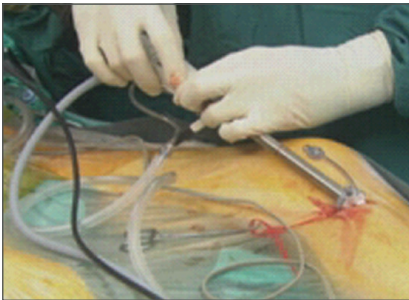


Figure 29a

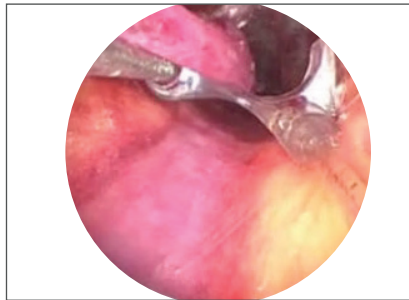


Figure 29b

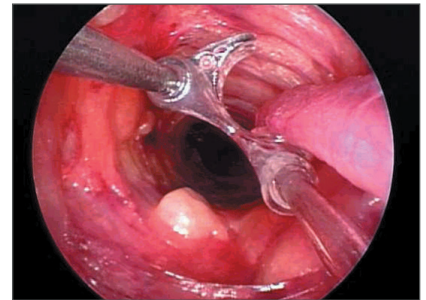


Figure 30

## Distal Transection and Ligation

Distal vessel transection can be performed in various ways. A “stab and grab” approach is used to pull the vein through a stab wound, where it is then externally transected. An “endoloop” approach divides the vein endoscopically, and is a technique used by some experienced operators.

### “Stab and Grab”

- With the tunnel insufflated, make a small 1 – 3 mm stab wound with an 11 blade over the distal end of the tunnel. The distal end of the tunnel can be identified with external manipulation.
- Observe on the video monitor as a hemostat or similar small clamp is inserted through the stab wound and

advanced into the tunnel. (Figures 31a and 31b) Under endoscopic vision, place the clamp across the distal end of the vein. Externalize the vein through the stab wound and divide it under direct vision per surgical protocol. (Figure 32) Allow the harvested vein segment to retract back into the tunnel.

- Ligate the terminal end of the vein stump per hospital protocol. Allow the ligated vein stump to retract back into the tunnel.

### Endoloop Approach

- This technique for performing distal vessel transection without the use of a skin incision, uses a knot pusher to pass a suture loop to the distal end of the tunnel. (Appendix A shows the steps for creating a ligation loop.)

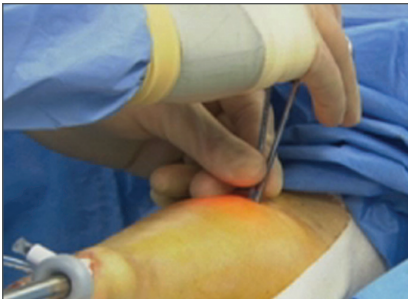

Figure 31a

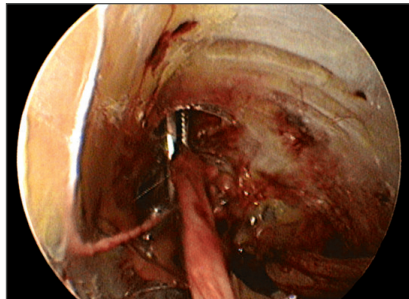


Figure 31b

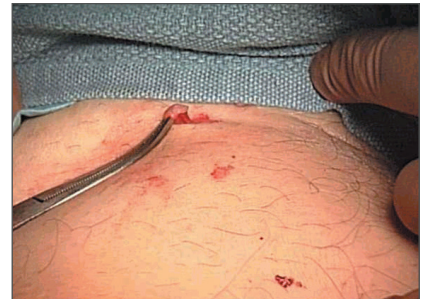

Figure 32

## Vein Removal and Preparation

- Turn off the CO<sub>2</sub> insufflation. Deflate the BTT balloon, if necessary, and remove the BTT from the incision.
- Check for any branches and adherent tissue at the site of the BTT in the tunnel. These branches may be transected under direct vision.
- Remove the saphenous vein through the incision. Note the anatomical orientation of the vein for proper cannulation of the vein for vessel preparation. Measure the vein to ensure adequate length for the bypass grafting. (Figure 33) If additional length is needed, further dissection can be carried out through the same incision, harvesting in the opposite direction.
- Flush and prepare the vein according to standard protocol.

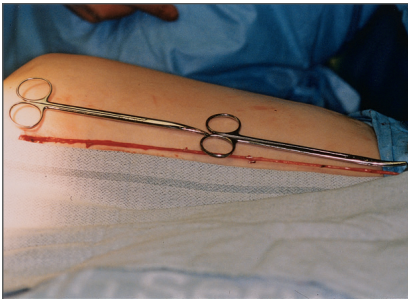


Figure 33

## Closing and Dressings

Close incisions using standard protocol. Apply dressings and wrap the leg according to standard protocol or operator preference.

### Technique Tips

- Using a lap sponge, gently roll along the skin over the operative area, expressing any residual blood through the incision prior to closing.
- Irrigate the operative tunnel, if desired. Roll out irrigant using the above technique.

# EVH Procedure

## Radial Artery

### Patient Positioning and Preparation

#### Preoperative Evaluation

When harvesting the radial artery, typically the non-dominant arm is used. Confirm adequate collateral circulation through the use of the pulse-assisted Allen's test, Doppler evaluation, pulse oximetry, or a combination of these tests as per standard hospital protocol. (Figure 34)

#### Surgical Preparation

Place the arm on surgical board, positioning it to no more than a 90-degree angle. For procedures using a tourniquet, select an appropriate size tourniquet and place the unpressurized tourniquet high on the upper arm before prep. Shave and prep the arm, using standard hospital protocol. (Figure 35)

#### Product Assembly

For additional product assembly information, see the Product Assembly section of the Endoscopic Vessel Harvesting of the saphenous vein portion of this manual.

- Attach the 7 mm Extended Length Endoscope to the camera coupler. Attach the light cable to the post on the endoscope. Focus the endoscope on a gauze pad and white balance the video camera. Ensure proper orientation of the camera head. It is important to maintain correct orientation throughout the procedure.
- Thread the Dissection Tip onto the distal end of the endoscope until the proximal edge of the Dissection Tip lines up with the indicator etched on the endoscope shaft.
- Place the Dissection Tip on a gauze pad. Focus the video camera, ensuring that the image outside the Dissection Tip is clearly visualized.
- Insert the endoscope with attached Dissection Tip through the BTT. Ensure that the Endoscope Seal is on the BTT. (The BTT is packaged with the Endoscope Seal attached.) (Figure 36)

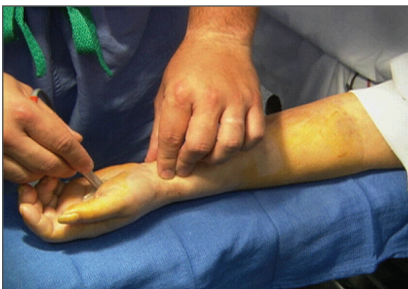

Figure 34

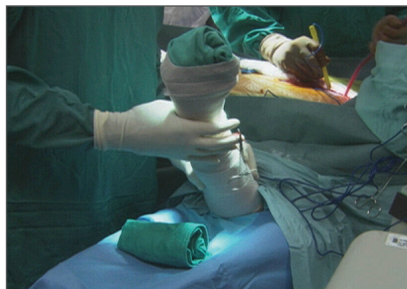

Figure 35

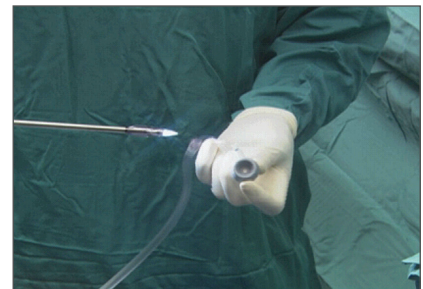

Figure 36

## Incision and Tourniquet Deployment

### Making the Incision

Create a 2 – 3 cm longitudinal incision over the radial artery from the wrist crease proximally. (As a point of orientation, the elbow area will be referred to as proximal and the wrist area will be referred to as distal.) (Figure 37)

### Initial Dissection Under Direct Vision

Under direct vision, dissect locally through the lateral muscular fascia to identify the radial artery and venae comitantes. (Figure 38)

### Tourniquet Deployment

In procedures using a tourniquet, wrap arm tightly with an Esmark bandage distal to proximal, from the fingers to the elbow. Inflate the tourniquet to 75 – 100 mmHg over systolic blood pressure, not exceeding 250 mmHg total. Remove the bandage. Extend the forearm, placing a rolled towel under wrist. Note time of tourniquet deployment. Generally tourniquet time is kept under one hour.

## Endoscopic Dissection

The radial artery is dissected as a pedicle with the accompanying venae comitantes, to minimize contact with, and potential spasm of the radial artery. Advance the endoscope over the anterior surface of the radial artery, about 4 cm's, to allow insertion of the BTT. Attach the CO<sub>2</sub> insufflation tubing to the clear flexible CO<sub>2</sub> Insufflation Port on the BTT and begin CO<sub>2</sub> insufflation at 10 – 12 mmHg and a flow rate of 3 – 5 L/min. If desired pressure is not obtained in the tunnel, the slip tip syringe provided can be used to inflate the balloon on the BTT. Inflate the balloon with the minimal amount of air needed to create an adequate seal (0 – 25 cc's of air).

(Notice that you do not achieve the same sized tunnel that you see during saphenous vein harvesting, which is in part due to the fascia constraining the tunnel. Later in the procedure, the fascia will be released, opening the tunnel.)

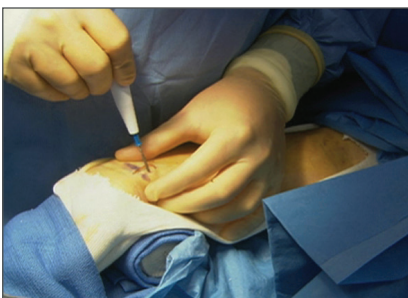

Figure 37

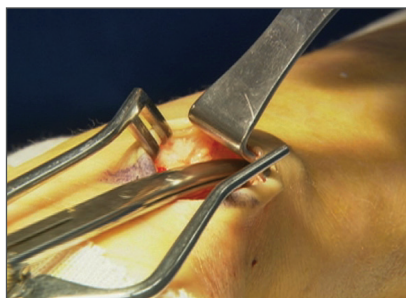


Figure 38



### Step 1: Anterior Dissection

With the aid of continuous CO<sub>2</sub> pressure, advance the Dissection Tip along the anterior surface of the radial artery. Note the venae comitantes on either side of the radial artery. Avoid direct contact with the radial artery. (Figures 39a and 39b) Dissect tissue and fascia away from the radial artery, lifting the Dissection Tip in an upwards direction. The lifting motion transmits shear force against the lateral muscular fascia and not the radial artery. Continue anterior dissection to the level of the recurrent radial artery or venous plexus in the antecubital fossa. As branches are encountered, advance past them with as little displacement as possible.

### Step 2: Posterior Dissection

Return the endoscope back to the BTT port. Carefully advance the endoscope posterior to the radial pedicle. Begin advancing the endoscope along the posterior aspect of the radial artery, again avoiding contact with the radial artery. Although anatomy varies from patient to patient, posterior branches are likely to be encountered midway up the forearm. When branches are encountered, free enough space around the branch to produce minimal stress to the branch as the Dissection Tip is advanced. Continue this dissection to the level of the recurrent radial artery. (Figures 40a and 40b)

### Step 3: Lateral Dissection

The purpose of lateral dissection is to create “windows” in or clear adjoining tissue from the pedicle. This is achieved by advancing the Dissection Tip through the targeted tissue.

To begin the lateral dissection, return the endoscope back to the BTT port. Larger branches may require creating a “window” through the tissue away from the pedicle creating additional exposure for later cautery. The final goal is obtaining a pedicle with both venae comitantes on both sides of the radial artery. Therefore, avoid any dissection between these structures.

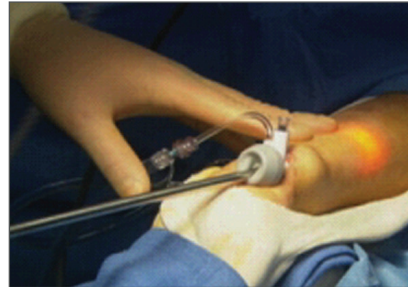

Figure 39a

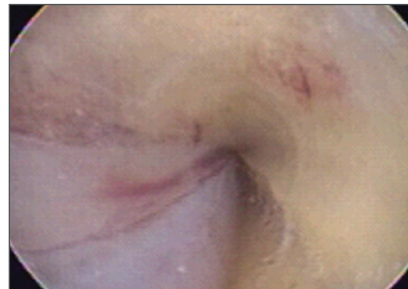

Figure 39b

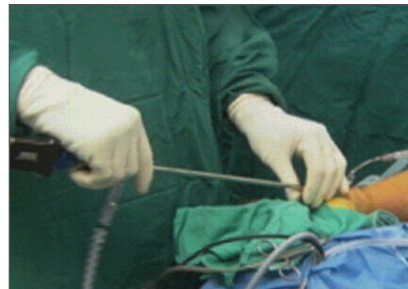

Figure 40a

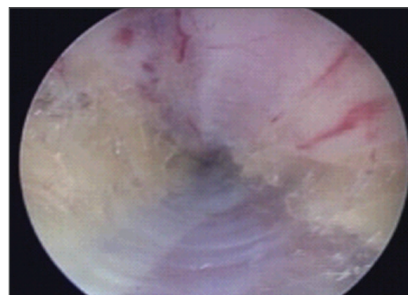


Figure 40b

## Fasciotomy

The fasciotomy is performed to enhance visualization by opening up the tunnel. Additionally, it can reduce the risk of compartment syndrome if there is any bleeding post-operatively.

To begin, withdraw the endoscope from the tunnel, leaving the BTT in place. Remove the Dissection Tip from the endoscope. Replace the 7 mm Endoscope Seal with the Harvesting Cannula Seal on the BTT. Insert the endoscope into the Vasoview 6 Pro Harvesting Cannula.

Using the BiSector™ Bipolar Ligating Forceps, perform fasciotomy using sharp transection, during which cautery is applied. Set the bipolar generator wattage according to recommendations in the Vasoview 6 Pro Instructions For Use (settings differ by type of generator). The fascia should be released from the distal forearm to the mid or proximal forearm. (Figures 41a and 41b)

## Branch Cauterization and Transection

Once the fasciotomy is complete, begin branch transection. Perform the branch cauterization and transection at a safe distance from the artery as with standard open technique. Use the C-Ring to stabilize the pedicle and to maintain a consistent distance between the pedicle and the BiSector tool. Using the C-Ring can ensure that the integrity of the radial artery conduit is preserved, by maintaining a distance of 3 – 5 mm between the pedicle and the BiSector tool during branch division. (Figure 42) Watch the vessel during cautery; typically only 1 – 2 seconds of cautery will be needed depending upon branch size. Work proximal to distal (elbow to wrist). The proximal end of the pedicle is indicated by the recurrent radial artery. Upon reaching the distal end of the pedicle, use the C-Ring to run the pedicle, ensuring that all branches have been transected.

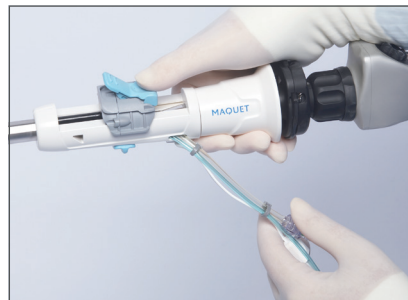

Figure 41a

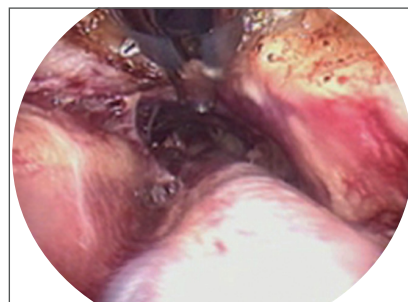

Figure 41b



Figure 42

## Transection and Retrieval of the Radial Artery

The radial artery pedicle can be transected and ligated using either the “stab and grab” technique with an 11-blade as described in the Distal Transection and Ligation section of the EVH Procedure for saphenous vein, or with a vessel loop, as described in Appendix A.

For procedures without a tourniquet, the radial pedicle should be clamped at the wrist with a soft bulldog-type clamp prior to proximal division. This is intended to keep the pedicle from bleeding into the tunnel.

Once the radial artery pedicle has been transected and ligated, allow both vessel segments to retract back into the tunnel. Remove the BTT port from the incision and withdraw the pedicle in a retrograde fashion externally through the incision. (Figure 43) Transect and ligate the radial artery at the wrist area using standard protocol. Note the anatomical orientation of the artery for proper cannulation of the artery for vessel preparation.

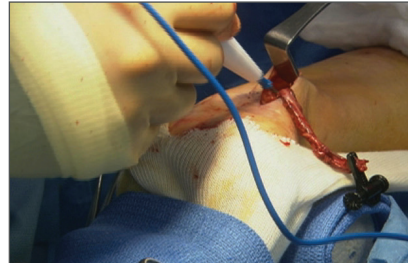


Figure 43



## Hemostasis and Conduit Preparation

The following information describes how to achieve hemostasis and close the incision. (Figures 44-47)

### Procedure – Non-tourniquet Method

Once the radial artery has been transected and ligated at the wrist, place the BTT port back into the incision. Place the Harvesting Cannula through the BTT port to inspect the tunnel for hemostasis. If necessary, some spot cautery can be performed for any additional hemostasis.

### Procedure – Using a Tourniquet

Deflate the tourniquet and note the tourniquet time. Check pulse oximetry on the digits to ensure adequate perfusion to the hand.

The incision and stab wound are closed per standard hospital protocol. Apply dressings and wrap the forearm according to standard protocol or operator preference.

The radial artery is prepared in the usual fashion per hospital protocol and operator preference. Soak and flush with desired solution. Clip or ligate branches per routine surgical practice.

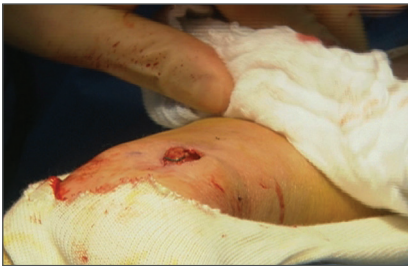

Figure 44

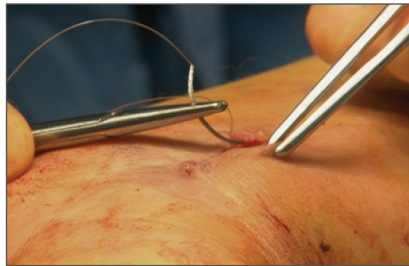


Figure 45

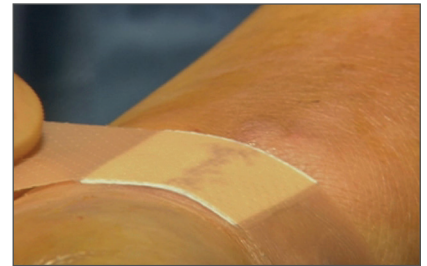

Figure 46

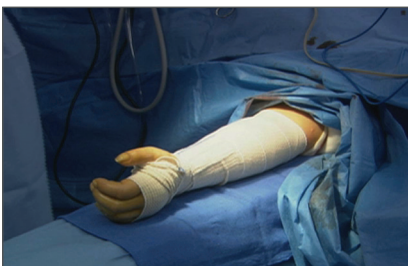

Figure 47

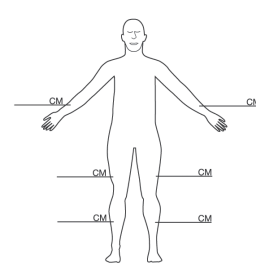
# Documentation

Use the forms included in the Vasoview 6 Pro Endoscopic Vessel Harvesting System kit to identify the location and the length of the vessel harvested. A sticker is included for the patient's hospital record, and a card is included for the patient. These will be helpful if a re-operation is needed.

**Hospital Record - Patient Information**

Ziekenuisadministratie – patientinformatie, Dossier d'hospitalisation – Informations relatives au patient, Krankenhausakte – Patienteninformationen, Cartella ospedaliera – Informazioni sul paziente, 病院記録 – 患者情報, Registro del hospital: Información del paciente, Registos do hospital – Informações do paciente, Sygehusejournal – Patientinformation, Sjukhusjournal – Patientinformation, Nemocióni záznam – Informace o pacientovi, Kórházi lelet – Beteg adatai, Rejestr szpitalny – informacja o pacjencie, Αρχειό νοσοκομείου – Στοιχεία ασθενούς

<p><b>Patient Name:</b> _____                  Naam patiënt: Nom du patient: Patientenname: Nome del paziente: 患者名: Nombre del paciente: Nome do paciente: Patientens navn: Patientens namn: Jméno pacienta: Páciens neve: Nazwisko pacjenta: Ονομα ασθενούς:</p> <p><b>Procedure:</b> _____                  Procedure: Procédure: Verfahren: Procedura: 処置: Procedimiento: Procedimento: Procedure: Ingrepp: Våkon: Eiljárás: Zabieg: Διαδικασία:</p> <p><b>Hospital:</b> _____                  Ziekenuis: Hôpital: Krankenhaus: Ospedale: 病院: Hospital: Hospital: Sygehus: Sjukhus: Nemocnice: Kórház: Szpítal: Νοσοκομείο:</p> <p><b>Procedure Date:</b> _____                  Datum procedure: Date de la procédure: Datum des Verfahrens: Data della procedura: 処置日: Fecha del procedimiento: Data do procedimento: Dato for proceduren: Datum för ingreppet: Datum výkonu: Eiljárás dátuma: Data zabiegu: Ημερομηνία διαδικασίας:</p> <p><b>Surgeon:</b> _____                  Chirurg: Chirurgien: Chirurg: Chiururgo: 外科医: Cirujano: Cirurgiã: Kirurg: Kirurg: Chirurg: Sebész: Chirurg: Χειρουργός:</p>	<p>An endoscopic technique was used to remove the vessel from: (circle one.)                  Het vat werd met behulp van een endoscopische techniek verwijderd uit: (lees optie omcirkelen)                  Une technique endoscopique a été utilisée pour retirer le vaisseau de: (entourer un choix)                  Eine endoskopische Technik wurde angewendet, um das Gefäß aus Folgendem zu entfernen: (eine Option einkreisen)                  È stata adottata una tecnica endoscopica per rimuovere il vaso da: (cerchiare una risposta)                  内視鏡術を従って、次の部位から血管を切除: (✓をつけて丸で囲む)                  Se utilizó técnica endoscópica para extraer el vaso de: (marcar con un círculo una opción)                  Foi utilizada uma técnica endoscópica para remover o vaso de: (assinalar uma das opções com um círculo)                  Der biev anvænt en endoskopisk teknik til fjernelse af karret fra: (sæt ring om svaret)                  Endoskopisk teknik har använts för att avlägsna kärlet från: (ringa in ett alternativ)                  Była použita endoskopická technika na odstranění cévy z: (zakroužkujte jednu možnost)                  Vredény endoszkópos technikával eltávolítva innen: (karikázzon be egyet)                  За pomocą techniki endoskopowej usunięto naczynie z: (zakreśl jedną odpowiedź)                  Χρησιμοποιήθηκε ενδοσκοπική τεχνική για την αφαίρεση του αγγείου από: (σημειώστε με κύκλο ένα)</p>
--	---



**MAQUET**  
PPL7000711 Rev. A

MAQUET Cardiovascular LLC.

Sticker for Hospital

**Patient Identification Card – Patientidentificatiekaart, Carte d'identification du patient, Patientenidentifikationskarte, Scheda di identificazione del paziente, 患者IDカード, Tarjeta de identificación del paciente, Cartão de identificação do paciente, Patientens identifikationskort, Patient-ID-kort, Identifikační karta pacienta, Betegazonosító kártya, Karta identyfikacyjna pacjenta, Κάρτα ταυρομνησής ασθενούς**

**Patient Name:** \_\_\_\_\_  
 Naam patiënt: Nom du patient: Patientenname: Nome del paziente: 患者名: Nombre del paciente: Nome do paciente: Patientens navn: Patientens namn: Jméno pacienta: Páciens neve: Nazwisko pacjenta: Ονομα ασθενούς:

**Procedure:** \_\_\_\_\_  
 Procedure: Procédure: Verfahren: Procedura: 処置: Procedimiento: Procedimento: Procedure: Ingrepp: Våkon: Eiljárás: Zabieg: Διαδικασία:

**Hospital:** \_\_\_\_\_  
 Ziekenuis: Hôpital: Krankenhaus: Ospedale: 病院: Hospital: Hospital: Sygehus: Sjukhus: Nemocnice: Kórház: Szpítal: Νοσοκομείο:

**Procedure Date:** \_\_\_\_\_  
 Datum procedure: Date de la procédure: Datum des Verfahrens: Data della procedura: 処置日: Fecha del procedimiento: Data do procedimento: Dato for proceduren: Datum för ingreppet: Datum výkonu: Eiljárás dátuma: Data zabiegu: Ημερομηνία διαδικασίας:

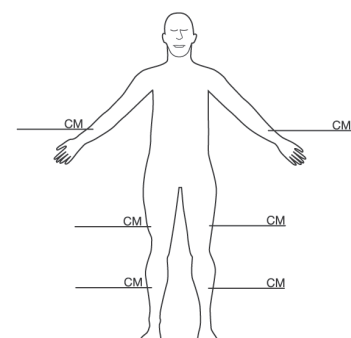
**Surgeon:** \_\_\_\_\_  
 Chirurg: Chirurgien: Chirurg: Chiururgo: 外科医: Cirujano: Cirurgiã: Kirurg: Kirurg: Chirurg: Sebész: Chirurg: Χειρουργός:

**MAQUET**  
PPL7000712 Rev. A

MAQUET Cardiovascular LLC.

Front of ID Card for Patient

**An endoscopic technique was used to remove the vessel from: (circle one.)**  
 Het vat werd met behulp van een endoscopische techniek verwijderd uit: (lees optie omcirkelen)  
 Une technique endoscopique a été utilisée pour retirer le vaisseau de: (entourer un choix)  
 Eine endoskopische Technik wurde angewendet, um das Gefäß aus Folgendem zu entfernen: (eine Option einkreisen)  
 È stata adottata una tecnica endoscopica per rimuovere il vaso da: (cerchiare una risposta)  
 内視鏡術を従って、次の部位から血管を切除: (✓をつけて丸で囲む)  
 Se utilizó técnica endoscópica para extraer el vaso de: (marcar con un círculo una opción)  
 Foi utilizada uma técnica endoscópica para remover o vaso de: (assinalar uma das opções com um círculo)  
 Der biev anvænt en endoskopisk teknik til fjernelse af karret fra: (sæt ring om svaret)  
 Endoskopisk teknik har använts för att avlägsna kärlet från: (ringa in ett alternativ)  
 Była použita endoskopická technika na odstranění cévy z: (zakroužkujte jednu možnost)  
 Vredény endoszkópos technikával eltávolítva innen: (karikázzon be egyet)  
 За pomocą techniki endoskopowej usunięto naczynie z: (zakreśl jedną odpowiedź)  
 Χρησιμοποιήθηκε ενδοσκοπική τεχνική για την αφαίρεση του αγγείου από: (σημειώστε με κύκλο ένα)



Back of ID Card for Patient

# Nursing Considerations

The OR staff plays an integral part in the endoscopic vessel harvesting procedure. It is crucial that the OR staff understands how the instrumentation and equipment are used, as well as the steps of the procedure, in order to create a cohesive team. The OR staff should be properly trained on the endoscopic vessel harvesting procedure as well as on the Vasoview system used. If the cardiovascular OR staff is not familiar with the videoscopic equipment, it is suggested that the manufacturer's local field representative also provide additional in-services. Equipment issues should not complicate the endoscopic procedure. All equipment should be tested and in good condition prior to beginning the case.

As with any new procedure, patience is required during the learning phase. Allow extra time for the OR staff and the operator during the first several procedures.

## **Circulating Nurse Responsibilities**

Knowing and understanding each component of the video setup is important for the circulating nurse, as the nurse is the primary troubleshooter once the procedure has begun. (See Troubleshooting Section)

Turn on all components to the video system, including those that may not be used. Once the various cords are handed off from the sterile field to the OR staff person in the non-sterile OR field, the following tasks are completed.

- Connect the camera cable to the camera box. The color bars are replaced by a clear image that is visible on the screen. Note that the light source settings—manual and automatic—correlate with the camera box settings, as do shutter controls and gain buttons. (Check with the video vendor for the proper settings.)
- Connect the fiber optic cable to the light source. Place the unit in the standby mode until the procedure begins. Be sure that the fiber optic cable is not resting against the patient or sterile drapes unless in the standby mode. There is potential for fire due to the intensity of the light. During this procedure, it may be necessary to increase the light intensity. Frequently, the light source unit can be set to manual for adjustment of the light intensity. The "gain" button generally boosts the light even further.
- Connect the insufflation tubing to the unit, verify settings, and place in standby mode until CO<sub>2</sub> is needed.
- Connect the bipolar cables to the generator and verify the generator settings.

# Case Setup

**Day before procedure:** Determine the best location for OR equipment (OR tables, perfusion, video tower, and anesthesia equipment) the day before the case to eliminate confusion on the day of surgery. The video tower is best positioned across from the vessel harvester.

**Day of procedure:** Begin with a Mayo stand or an area of the back table that can be devoted to the Vasoview products. The advantage of a separate Mayo stand is that it can be removed from the field once the vessel harvesting is completed and to simplify the general set-up.

## **Sterile items:**

- Components of the Vasoview 6 Pro EVH system kit:
  - Vasoview 6 Pro Harvesting Cannula with integrated BiSector™ Bipolar Ligating Forceps and C-Ring
  - Short Port BTT with 7 mm Endoscope Seal, Harvesting Cannula Seal, and Dissection Tip
- Camera head
- 7 mm Extended Length Endoscope
- Fiber optic cable
- Insufflation tubing
- Bipolar cord
- Anti-fog solution (optional)
- Scalpel handle
- #10 blade, #11 blade
- Army/Navy retractor
- 6-inch or 7-inch right-angle hemostat
- 6-inch or 7-inch Crile or Kelly hemostat
- Ligature (manual clips, small and medium, with appliers or suture)
- Items available but not opened:
  - Minor instrument set
  - Back-up sterile endoscope

## **Non-sterile items:**

- Endoscopic video cart (video monitor, camera, light source, and insufflator)
- Bipolar generator and foot pedal

# Postoperative Procedures

For the most part, the postoperative procedures will remain consistent with those practiced for the open harvest technique.

## **Suggestions**

- Care must be taken when handling the 7 mm endoscopes; these endoscopes are longer and more fragile than shorter or larger-diameter endoscopes. It is recommended that the endoscopes be kept in a protective instrument tray.
- Create a Vasoview system supply cart. Keep all related supplies on the cart, including back-up kit components. It is easy for something to fall on the floor or become contaminated.
- Designate someone to restock the cart.
- Consider making one person the resident expert with the Vasoview Endoscopic Vessel Harvesting System.

# Troubleshooting

Occasionally, the operator may encounter problems while performing the endoscopic vessel harvesting procedure. Most situations can be managed easily with a quick check of the equipment. If problems arise, stop the procedure and check these items.

## No Tunnel/No CO<sub>2</sub>

- CO<sub>2</sub> tank is full and opened.
- CO<sub>2</sub> tubing is connected to the BTT and the insufflator.
- Flow and pressure settings on insufflator (3 – 5 L/mm and 10 – 12 mmHg).
- CO<sub>2</sub> leaking around incision.
- Ensure the BTT has been inserted correctly into the tunnel.
- Verify CO<sub>2</sub> tubing is not improperly connected to the BTT balloon port

## No Cauterization

- Generator is set on bipolar.
- Generator is plugged in.
- Correct bipolar foot pedal is being used.
- Bipolar pedal is connected to the appropriate generator port.
- Correct wattage is set in the generator based on the brand-specific recommendation (refer to BiSector™ Bipolar Ligating Forceps Instructions For Use).
- Bipolar Cord is connected to the Harvesting Cannula electrical cord.
- Bipolar cord is functioning properly.

## Endoscope “Sliming”

- When advancing instruments, ensure that they are maintained in a central position in the tunnel.
- Ensure that tissue is not on the C-Ring before withdrawing into the C-Ring into the Harvesting Cannula.
- Attempt to clean the endoscope lens on tunnel wall.
- Remove the scope and clean it externally.
- Use the scope washer within the Harvesting Cannula to clean the lens.

## Endoscope Fogging

- Use anti-fog solution on the end of the endoscope (only when the endoscope is in the Vasoview 6 Pro Harvesting Cannula; do not use anti-fog solution on the lens prior to placement of the Dissection Tip.)
- Withdraw the distal tip of the endoscope back to the BTT, keeping the instrument in the tunnel. Hold in place for about 10 seconds. This allows cold CO<sub>2</sub> to infuse directly over the tip of the endoscope and clears the fogging (similar to using air conditioning in a car to clear a fogged windshield).

## Picture of the Tunnel is Too Dark

- Light cable is connected to the endoscope and the light source.
- Re-white balance the endoscope.
- Increase the gain on the camera.
- Increase the light intensity.
- Change the light cable.
- Blood absorbs light; if blood is in tunnel, try rolling it out through the incision.
- Position the operative lights over the external working area of the leg to transilluminate the tunnel.
- Try replacing the endoscope and check the fiber optics of endoscope after the procedure is completed.

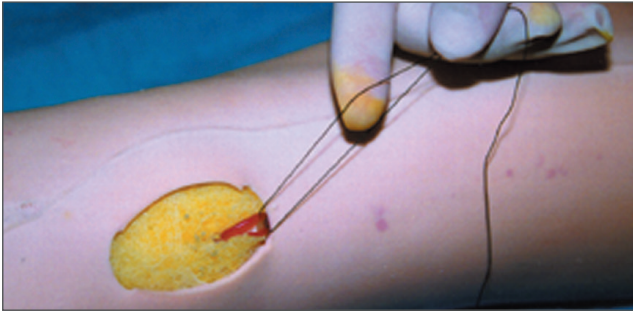
## Blood in the Tunnel

- Remove the BTT. Using a lap sponge, gently roll along the tunnel toward the incision, expressing blood through the incision.
- Remove the BTT. Insert a Yankauer suction into the incision and suction pooled blood from the tunnel.
- Remove the BTT. Irrigate with non-heparinized normal saline. Roll the tunnel externally to remove irrigation and re-insert the BTT and continue with insufflation.



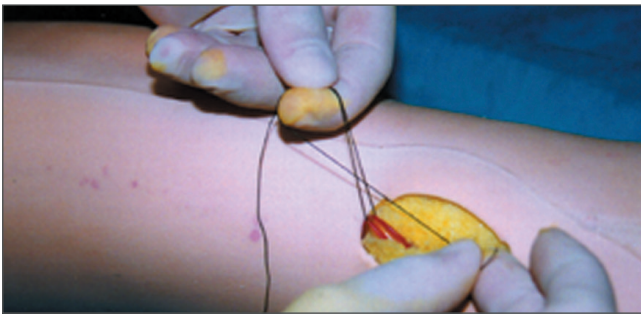
# Appendix A: Endoloop Approach

## Eight Steps for Tying a Ligation Loop



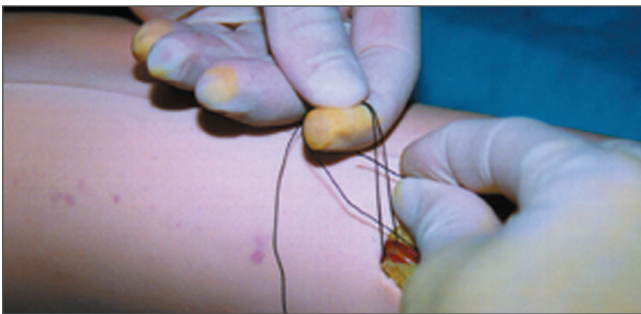
**Step 1:**

Using a monofilament suture, grasp both suture ends between the thumb and index finger as shown.



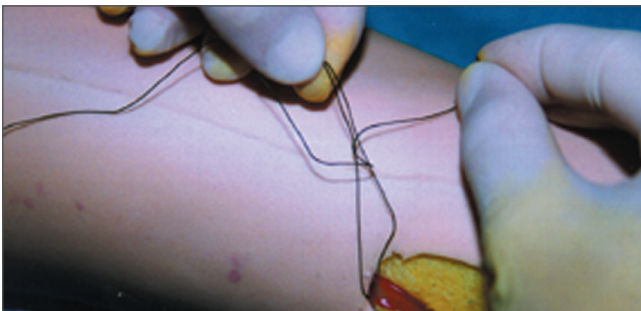
**Step 2:**

Take the shortest suture tail in front of the 2 sutures, forming a complete circle around the index finger.



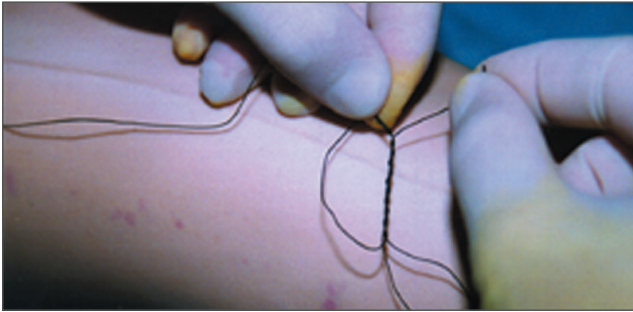**Step 3:**

Take the shortest suture strand in back of the 2 suture strands and pass the short strand through the circle.



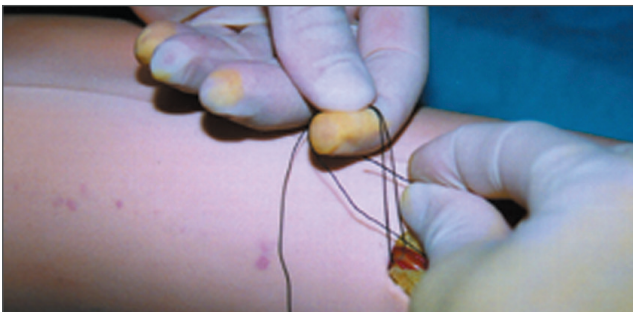
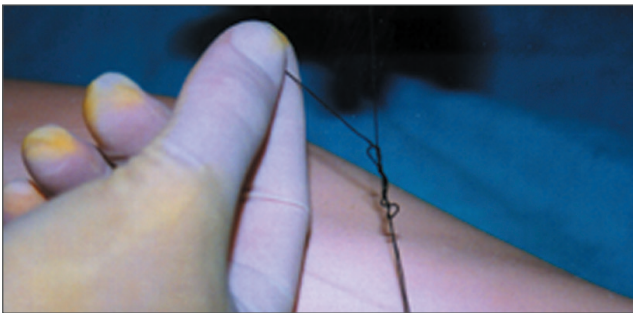
**Step 4:**

Grasp the short strand and pull through the circle and begin process over, wrapping short strand a total of 5 times in the circle.



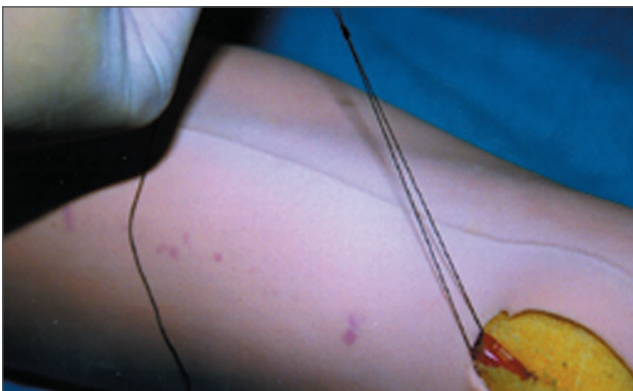
**Step 5:**

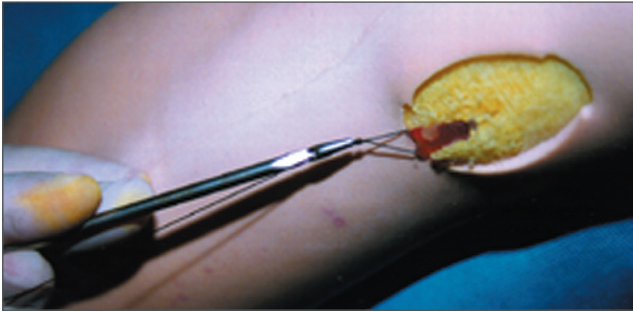
Pull short and long strand to tighten knot.



**Step 6:**

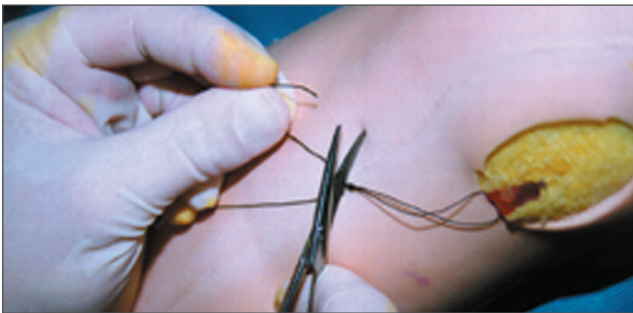Pull short strand and one of the 2 strands to tighten knot securely. Remember, one of the strands will tighten the knot and one will advance the knot.





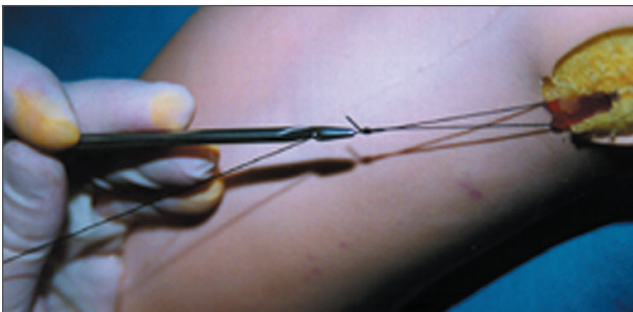
**Step 7:**

Once the knot is secure, cut the short tail, leaving 2 to 3 mm of suture. Do not cut right next to the knot.



**Step 8:**

Thread the knot pusher and advance knot and knot pusher into insufflated tunnel. (Push the knot to the ligation point and cinch the suture around the vein. The suture is secure and tight when the vein has an hourglass appearance.)









MCV00013301 REVD · 04/2020 · Protected by the following international and U.S. patent(s):<http://patents.maquet.com>. ·  
Getinge and are trademarks or registered trademarks of Getinge AB, its subsidiaries or affiliates in the United States or  
other countries · Copyright 2020 Getinge · All rights not expressly granted are reserved. · Printed in U.S.A.

Getinge · 45 Barbour Pond Dr · Wayne, NJ 07470 · USA · +1 888 627-8383

[www.getinge.com](http://www.getinge.com)